

## CLINICAL VIGNETTE

---

# Non-sustained Ventricular Tachycardia during Oxytocin Infusion for Uterine Atony

---

Kenneth Liu, MD and Peter Drocton, MD

### *Introduction*

Intravenous oxytocin is commonly used in labor and delivery units for the induction of labor and stimulation of uterine contractions, as well as for the prophylaxis and treatment of postpartum hemorrhage associated with uterine atony. However, oxytocin has been found to have significant hemodynamic and cardiovascular effects limiting its safety profile. This report describes a case of non-sustained ventricular tachycardia associated with oxytocin administration complicating cesarean delivery.

### *Case Report*

A multiparous 33 year-old pregnant female with several prior cesarean deliveries presented for a scheduled repeat cesarean delivery at 39 weeks gestation. Her prenatal care was notable only for the treatment of anemia with iron supplementation, and CBC the morning of her operation showed a hemoglobin concentration of 10.5 g/dL. She described a normal functional capacity with no cardiopulmonary symptoms during her preoperative physical.

In the operating room, initial evaluation showed sinus rhythm without electrocardiographic abnormalities and unremarkable vital signs. Anesthesia was administered in a standard fashion via intrathecal injection of 12 mg of hyperbaric bupivacaine, 15 mcg of fentanyl, and 200 mcg of morphine. Prior to the start of the surgery, antibiotic prophylaxis with cefazolin and 4 mg of ondansetron were also given. The patient had no complaints at the onset of the surgery and up to the time immediately following delivery of the neonate. The blood loss was estimated to be about 600 mL following delivery, and a routine infusion of oxytocin was started via rapid administration of 30 units (U) of oxytocin added to a liter saline bag.

Approximately 12 minutes following delivery and oxytocin infusion, the patient began to complain of mid-sternal chest pain and pressure without shortness of breath. Her vital signs were normal, though the heart rate approached 100 bpm at times of significant discomfort. The EKG changed to sinus rhythm with 5 to 10 premature ventricular contractions per minute, which quickly increased to short runs of non-sustained ventricular tachycardia with a rate of approximately 150 bpm (Figure 1). The episodes of ventricular tachycardia occurred about once every minute. She complained of moderate chest pain during the times of frequent ventricular ectopy with symptom resolution during brief returns to sinus rhythm.

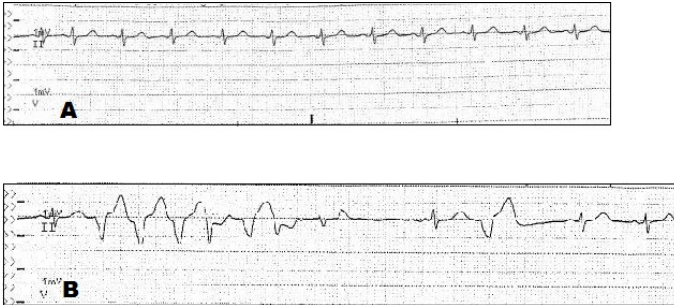
Intravenous morphine 3 mg with a rapid fluid bolus was given, and because there was no significant postpartum hemorrhage from uterine atony, the oxytocin infusion was stopped about 15 minutes after symptoms first appeared. All ventricular ectopy and chest pain resolved within 10 minutes of stopping the oxytocin infusion, and she remained in normal sinus rhythm until the end of the case and for two hours in the postanesthesia care unit. Laboratory evaluation of complete blood count, metabolic panel, and blood gas sampled intraoperatively showed slight abnormalities of potassium (3.4 mEq/L) and magnesium (1.4 mEq/L). There were no remarkable events in the immediate postpartum period and during her two postoperative days prior to hospital discharge.

### *Discussion*

Oxytocin possesses various hormonal activities given that receptors for oxytocin are found in a wide range of tissue outside of myometrium and mammary glands, including myocardium, vascular smooth muscle, gonads, and kidneys.<sup>1</sup> Investigations of parturients injected with oxytocin while undergoing advanced hemodynamic monitoring show decreases in systemic vascular resistance and systolic/mean arterial pressures with increases in cardiac output and heart rate.<sup>2,3</sup> Furthermore, there are prior reports of signs and symptoms of myocardial ischemia during oxytocin infusion.<sup>4,5</sup> In a study of 103 parturients, a bolus of either 5 U or 10 U of oxytocin following cord clamping during cesarean delivery produced ST depressions in 7.7% and 21.6% of cases, respectively.<sup>5</sup> These boluses of oxytocin were also frequently associated with symptoms such as chest pain and dyspnea.

Given these undesired cardiovascular effects of oxytocin, several studies have investigated the optimal dosing of oxytocin infusions for the treatment of uterine atony during cesarean delivery.<sup>6-8</sup> For example, the drop in hemoglobin following uncomplicated cesarean surgery was similar among 189 women receiving either 20, 30, or 40 U of oxytocin diluted in 500 mL of crystalloid.<sup>6</sup> Another study demonstrated significantly less oxytocin could be delivered for adequate uterine tone if a timed algorithm of 3 U oxytocin boluses was utilized compared to a standard continuous infusion of 30 U of oxytocin/500 mL of normal saline.<sup>7</sup> These studies suggest that oxytocin doses lower than those commonly used in practice may be effective and may mitigate adverse effects.

This case describes the onset of non-sustained ventricular tachycardia with the rapid administration of oxytocin and is an example of one of the most commonly used medications in labor and delivery units producing a life-threatening reaction. Given the cardiovascular effects of rapid oxytocin infusion, clinicians should be wary of delivering more oxytocin than necessary for producing adequate hemostasis and consider holding the medication in situations of hypotension, tachycardia, cardiac ischemia, or arrhythmia.



**Figure 1.** Patient's electrocardiogram during onset of surgery (A) and oxytocin infusion after delivery (B).

## REFERENCES

1. **Gimpl G, Fahrenholz F.** The oxytocin receptor system: structure, function, and regulation. *Physiol Rev.* 2001 Apr;81(2):629-83. Review. PubMed PMID: 11274341.
2. **Langesaeter E, Rosseland LA, Stubhaug A.** Haemodynamic effects of repeated doses of oxytocin during Caesarean delivery in healthy parturients. *Br J Anaesth.* 2009 Aug;103(2):260-2. doi: 10.1093/bja/aep137. Epub 2009 Jun 5. PubMed PMID: 19502285.
3. **Archer TL, Knape K, Liles D, Wheeler AS, Carter B.** The hemodynamics of oxytocin and other vasoactive agents during neuraxial anesthesia for cesarean delivery: findings in six cases. *Int J Obstet Anesth.* 2008 Jul;17(3):247-54. doi: 10.1016/j.ijoa.2008.03.003. Epub 2008 May 29. PubMed PMID: 18513945.
4. **Svanström MC, Biber B, Hanes M, Johansson G, Näslund U, Bålfors EM.** Signs of myocardial ischaemia after injection of oxytocin: a randomized double-blind comparison of oxytocin and methylergometrine during Caesarean section. *Br J Anaesth.* 2008 May;100(5):683-9. doi: 10.1093/bja/aen071. Epub 2008 Apr 2. PubMed PMID: 18385263.
5. **Jonsson M, Hanson U, Lidell C, Nordén-Lindeberg S.** ST depression at caesarean section and the relation to oxytocin dose. A randomised controlled trial. *BJOG.* 2010 Jan;117(1):76-83. doi: 10.1111/j.1471-0528.2009.02356.x. PubMed PMID: 19781043.
6. **Ghulmiyyah LM, Usta IM, Ghazeeri G, Taher N, Abu-Ghannam G, Tamim H, Nassar AH.** Intravenous Oxytocin Use to Decrease Blood Loss during Scheduled Cesarean Delivery: A Randomized Double-Blinded Controlled Trial (OXYTRIAL). *Am J Perinatol.* 2017 Mar;34(4):379-387. doi: 10.1055/s-0036-1592130. Epub 2016 Sep 2. PubMed PMID: 27588932.
7. **Kovacheva VP, Soens MA, Tsen LC.** A Randomized, Double-blinded Trial of a "Rule of Threes" Algorithm versus Continuous Infusion of Oxytocin during Elective Cesarean Delivery. *Anesthesiology.* 2015 Jul;123(1):92-100. doi: 10.1097/ALN.0000000000000682. PubMed PMID: 25909969.
8. **Duffield A, McKenzie C, Carvalho B, Ramachandran B, Yin V, El-Sayed YY, Riley ET, Butwick AJ.** Effect of a High-Rate Versus a Low-Rate Oxytocin Infusion for Maintaining Uterine Contractility During Elective Cesarean Delivery: A Prospective Randomized Clinical Trial. *Anesth Analg.* 2017 Mar;124(3):857-862. doi: 10.1213/ANE.0000000000001658. PubMed PMID: 28212181; PubMed Central PMCID: PMC5319709.